

## CLINICAL REPORT

# Topical Photodynamic Therapy for Prevention of New Skin Lesions in Renal Transplant Recipients

Hans Christian WULF<sup>1</sup>, Stan PAVEL<sup>2</sup>, Ida STENDER<sup>1</sup> and Christianne AHB BAKKER-WENSVEEN<sup>2</sup>

<sup>1</sup>Department of Dermatology, University of Copenhagen, Bispebjerg Hospital, Copenhagen, Denmark and <sup>2</sup>Department of Dermatology, Leiden University Medical Center, Leiden, The Netherlands

**Preclinical data suggest that topical methyl aminolevulinate photodynamic therapy may have potential in preventing new skin lesions in transplant recipients. An open intra-patient randomized study investigated the prevention potential of this treatment in 27 renal transplant patients with actinic keratoses and other skin lesions in two circular contralateral areas (5 cm diameter). The treatment area surface was debrided and methyl aminolevulinate cream (160 mg/g) was applied for 3 h prior to illumination by non-coherent red light (570–670 nm, light dose 75 J/cm<sup>2</sup>). The control area was not treated. The mean time to occurrence of the first new lesion was significantly longer in treated than control areas (9.6 vs 6.8 months, treatment difference 2.9 [95% confidence interval 0.2 to 5.5] months,  $p=0.034$ ). Over 12 months, 62% (16/26) of treated areas were free from new lesions compared with 35% (9/26) in control areas. These findings indicate that topical methyl aminolevulinate photodynamic therapy is a promising preventive treatment against new skin lesions in immunosuppressed patients. Key words: methyl aminolevulinate; immunosuppressed patients; skin cancer.**

(Accepted May 6, 2005.)

Acta Derm Venereol 2006; 86: 25–28.

Hans Christian Wulf, Dermatology Department D42, Bispebjerg Bakke 23, 2400 København NV, Denmark. E-mail: hcw01@bbh.hosp.dk

Increased risk of non-melanoma skin cancer is a recognized complication of long-term immunosuppression in transplant recipients. Within 5 years of solid organ transplantation, up to 40% of patients develop premalignant skin lesions such as actinic keratoses (AK) and 90% have warts, many of which are atypical and in sun-exposed areas (1–3). The development of such keratotic lesions is closely associated with aggressive forms of squamous cell carcinoma (SCC), with prevalence 40–250-fold greater than that observed in the general population (4). Together these factors contribute to a 10-fold increase in mortality due to SCC in transplant patients compared with the general population.

Current management strategies are aimed at preventing the development of new lesions as well as minimizing progression of premalignant lesions to invasive

SCC. Although various therapies are available, most are hampered by considerable discomfort during treatment and in many cases lead to scarring and less than optimal cosmetic outcome (5).

Photodynamic therapy (PDT), a treatment modality that involves the use of a photosensitizing agent and light of a specific wavelength to produce lesion-specific cell death, could represent a promising prophylactic alternative. Two topical photosensitizers may be used – 5-aminolevulinate (ALA) and methyl aminolevulinate (MAL), the methyl ester of ALA. MAL offers advantages over ALA in terms of improved skin penetration due to enhanced lipophilicity (6, 7) and greater specificity for neoplastic cells (8). Additionally, preclinical data have shown that topical MAL and ALA PDT inhibit the development of ultraviolet-induced SCC in hairless mice (9, 10). Based on these findings, the current study was undertaken to investigate the potential of MAL PDT for prevention of new premalignant lesions in immunosuppressed solid organ transplant patients.

## MATERIALS AND METHODS

Between July 1999 and March 2000, 28 adult renal transplant recipients with two circular contralateral areas (5 cm diameter) on the face or dorsal side of the hands with at least two clinically diagnosed AK lesions and a maximum of 10 skin lesions (AK, basal cell carcinoma [BCC] and/or warts) in each area, were enrolled in this open study by two hospital dermatology outpatient centres (one each in Denmark and the Netherlands). AK lesions were graded on the basis of palpation and observation as mild, moderate or severe (11); BCC lesions were characterized as superficial or nodular; and warts were characterized as verruca plana, small keratotic papilloma (longest diameter <0.5 cm) or large keratotic papilloma (longest diameter >0.5 cm). All patients should have received immunosuppressive therapy for >3 years. Exclusion criteria were clinical SCC, keratoacanthoma, infiltrating tumours, rosacea or acne in the treatment area; psoriasis, atopic dermatitis, eczema or porphyria; known allergy to the study treatment or similar compounds; likelihood of non-compliance; participation in another study; or women who were pregnant or breast-feeding. Topical therapy of the treatment site in the last month or concurrent systemic retinoid therapy was prohibited. The study was approved by the local ethics committee and conducted in accordance with the Declaration of Helsinki. All patients gave written informed consent prior to entry.

For each patient, the two contralateral areas were randomly assigned to treatment or no treatment (i.e. control) by the investigator, according to a computer-generated list. Following

surface debridement, a 1 mm thick layer of MAL cream (160 mg/g, Metvix®, PhotoCure, Oslo, Norway) was applied to the whole treatment area, including existing lesions, and 5 mm of surrounding skin and covered with an adhesive occlusive dressing (e.g. Tegaderm®, 3M). After 3 h, the dressings were removed and the cream was washed off with 0.9% saline solution, immediately prior to illumination with non-coherent red light (Curelight® lamp supplied by PhotoCure, Oslo, Norway) with wavelength 570–670 nm and light dose 75 J/cm<sup>2</sup>. The corresponding control area was not treated.

At baseline and every 2 months for 12 months, the location and margins of all lesions were carefully mapped in body charts and photographed. The occurrence of any new visible lesion in the treatment and control areas was evaluated by the same dermatologist in each centre. Adverse events were monitored during treatment and 1 week and 2 months post-treatment. Local skin/phototoxicity reactions were graded according to the National Cancer Institute Common Toxicity Criteria for skin (12). Adverse events were rated as mild, moderate or severe, and the causal relationship of the event to the study treatment was assessed by the clinician as related, uncertain or not related.

### Statistical analysis

The primary variable was the time to occurrence of a new skin lesion observed in treated and control areas up to 12 months post-treatment. Assuming that the time to occurrence of new lesions would be 6 months in the control area and 8 months in the treated area (standard deviation of difference 4 months), at least 25 evaluable patients were required to be able to conclude with a probability of 80% that there was a treatment difference.

The difference in time to occurrence of new lesions between treated and control areas within each patient was compared using the paired *t*-test. If a patient had no new lesions in either treated or control areas, the time to occurrence was given as 13 months. Additionally, Kaplan-Meier estimates and 95% confidence interval (95% CI) for the median time to occurrence of at least one new lesion were calculated for treated and control areas and compared using the log rank test.

## RESULTS

Twenty-seven of the 28 enrolled patients, 17 men and 10 women aged 32–75 years (mean 57 years), received a single MAL PDT. All patients were Caucasian and the mean time since transplantation was 15.9 years (range 4.2–32.5 years). One patient was not treated as he had more than 10 lesions on one hand. Twenty-four patients completed the study; two patients died following myocardial infarction 6 and 8 months after treatment, and one patient withdrew consent during follow-up. Neither case of myocardial infarction was considered to be related to the study treatment.

The 27 patients had a total of 263 lesions, 135 in the treatment area and 128 in the control area. Most patients (21/27, 78%) had up to six lesions in both treatment and control areas. The distribution of lesions at baseline is shown in Table I. Treatment procedures were in accordance with the specified schedule, with a mean cream application time of 3 h and 3 min (range 2 h 55 min to 4 h) and mean illumination time of 15 min and 13 s (range 7–23 min).

Table I. Lesion characteristics at baseline

Parameter	Treated area	Control area
Total number of lesions	135	128
Actinic keratoses, <i>n</i> (%)	98 (73)	80 (62)
Thin	52 (39)	49 (38)
Moderate	44 (33)	30 (23)
Thick	2 (1)	1 (1)
Warts, <i>n</i> (%)	37 (27)	48 (38)
Verruca plana	8 (6)	12 (9)
Small keratotic papilloma	27 (20)	28 (22)
Large keratotic papilloma	0 (0)	2 (2)
Verruca seborrhoica	2 (1)	6 (5)
Lesion location, <i>n</i> (%)		
Face	24 (18)	29 (23)
Actinic keratoses	19 (14)	22 (17)
Warts	5 (4)	7 (6)
Hand	111 (82)	99 (77)
Actinic keratoses	79 (59)	58 (45)
Warts	32 (23)	41 (32)

### Efficacy

The mean time to occurrence of a new skin lesion (AK, BCC, keratoacanthoma, SCC or warts) was significantly longer in the treated area than the control area (9.6 vs 6.8 months, treatment difference 2.9 [95% CI 0.2 to 5.5] months, *p*=0.034). There was no significant difference between the two centres. Kaplan-Meier estimates of the probability of occurrence also favoured a longer time to occurrence of a new lesion in treated than control areas (*p*=0.05) (Fig. 1). Although there was no significant difference between treated and control areas with respect to the occurrence of specific types of new lesions (due to the small numbers of new lesions), more than twice as many patients had the first occurrence of a new lesion in a control area than treated area (48% vs 19%). Moreover, at the end of the 12-month follow-up period, 62% (16/26) of the patients were free from new lesions in treated areas compared with 35% (9/26) in control areas (Table II). In the control area, 38% of the patients had new lesion(s) after 2 months and after 12 months in the treated area. Most new le-

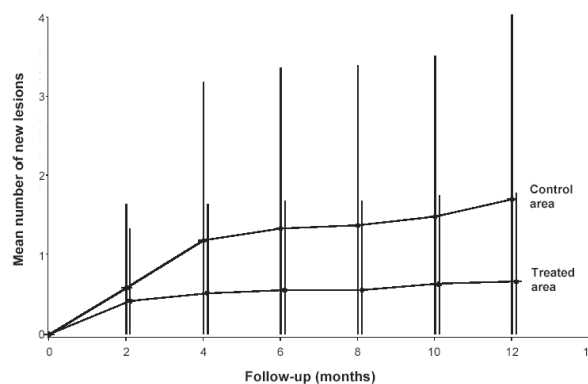


Fig. 1. Number of new lesions (mean ± SD) in treated and control area after one methyl aminolevulinate-photodynamic therapy.

sions were AKs; no new clinical SCC or BCC lesions were observed. The number of lesions per treated area (in which lesions occurred) was almost consistently below 2, whereas the number increased with time in the affected control areas (Table II).

### Tolerability

In total, 26/27 (96%) patients reported local adverse events. Treatment-related local adverse events were consistent with the known adverse event profile for PDT, with local phototoxicity reactions such as burning sensation (19/27, 70%), erythema (7/27, 26%) and stinging skin (6/27, 22%) most commonly reported. With the exception of one report, all local adverse events were of mild to moderate intensity. All cases of burning, erythema and stinging skin resolved within 5 days.

## DISCUSSION

The results of this study indicate the potential of MAL PDT as a preventive treatment for premalignant lesions in immunosuppressed patients. In fact, the same number of patients (38%) had new lesions after 2 months in the control area as after 12 months in the treatment area. Also the absolute number of new lesions was about three times higher in the control areas than in the treated areas after 12 months (Table II). The relatively small number of lesions did not permit comparison for individual lesion types. We only used one PDT treatment in this study and therefore did not expect an optimal treatment effect on existing lesions. The lesion response at 4 months was 56% for AK and 37% for warts.

The two most important risk factors for skin cancer in the transplant population are the extent of sunlight exposure (13) and the age at transplantation (14). Exposure to sunlight was not recorded in the current study; however, the median age at transplantation was 44 years in one centre and 41 years in the other, thus exceeding 35 years, which is associated with a higher risk of skin cancer development (15).

Retinoid therapy (e.g. tretinate, acitretin and topical tretinoin) has been advocated as a preventive treatment for the development of new keratotic lesions and recurrence of SCC in this patient group (16, 17). While studies have shown that retinoid therapy is effective in decreasing the risk of skin cancer in transplant patients (18–20) there is some concern that these agents may potentiate graft rejection (4), and poor tolerability (teratogenicity, severe mucocutaneous dryness, liver toxicity, elevated cholesterol and triglyceride levels) is a major limiting factor associated with retinoid therapy (17, 20). Moreover, treatment needs to be given long term to prevent relapse of premalignant and malignant skin lesions (4,16).

By contrast, MAL PDT offers a number of advantages over retinoid prophylaxis. PDT with MAL is devoid of systemic side effects. Systemic uptake is negligible, and therefore MAL PDT has no potential for interaction with systemic immunosuppressiva. Because of the excellent cosmetic outcome with MAL PDT, the clinician can use it prophylactically on 'normal' skin, a particularly pertinent advantage when used on cosmetically sensitive areas such as the face and hands (21–25).

The purpose of this study was to investigate the prophylactic possibilities of MAL PDT in solid organ transplant patients after one treatment with MAL PDT. The encouraging results of this pilot study warrant further investigation of MAL PDT as a preventive treatment for the development of skin lesions in transplant patients.

## ACKNOWLEDGEMENT

This study were funded by PhotoCure ASA, Oslo, Norway.

## REFERENCES

1. Leigh IM, Glover MT. Skin cancer and warts in immunosuppressed renal transplant recipients. *Recent Results Cancer Res* 1995; 139: 69–86.

Table II. Number (%) of areas with total prevention of new lesions after one MAL PDT\*

Time point	Total prevention		No prevention	
	Treated area n (%)	Control area n (%)	Treated area n (mean/area)	Control area n (mean/area)
Baseline	0	0	0	0
Month 2 <sup>a</sup>	19 (73)	16 (62)	11 (1.6)	15 (1.5)
Month 4	20 (74)	12 (44)	14 (2.0)	32 (2.1)
Month 6	19 (70)	11 (41)	15 (1.9)	36 (2.3)
Month 8	19 (70)	11 (41)	15 (1.9)	37 (2.3)
Month 10	17 (63)	9 (33)	17 (1.7)	40 (2.2)
Month 12 <sup>a</sup>	16 (62)	9 (35)	16 (1.6)	45 (2.6)

\*In case of new lesions in the areas (no prevention), the total number of lesions and the mean number per area is given. Number of treated and control areas was 27.

<sup>a</sup>Assessment missing for both lesion areas in one patient.

2. Stockfleth E, Ulrich C, Meyer T, Christophers E. Epithelial malignancies in organ transplant patients: clinical presentation and new methods of treatment. *Recent Results Cancer Res* 2002; 160: 251–258.
3. Dreno B, Mansat E, Legoux B, Litoux P. Skin cancer in transplant patients. *Nephrol Dial Transplant* 1998; 13: 1374–1379.
4. Wu JJ, Orenge IF. Squamous cell carcinoma in solid-organ transplantation. *Dermatology Online Journal* 2002; 8: 4.
5. Berg D, Otley CC. Skin cancer in organ transplant recipients: epidemiology, pathogenesis, and management. *J Am Acad Dermatol* 2002; 47: 1–17.
6. Peng Q, Moan J, Warloe T, Iani V, Steen HB, Bjorseth A, et al. Build-up of esterified aminolevulinic-derivative-induced porphyrin fluorescence in normal skin. *J Photochem Photobiol B Biol* 1996; 34: 95–96.
7. Kloek J, Beijersbergen van Henegouwen MJ. Prodrugs of 5-aminolevulinic acid for photodynamic therapy. *Photochem Photobiol* 1996; 64: 994–1000.
8. Fritsch C, Homey B, Stahl W, Lehmann P, Ruzicka T, Sies H. Preferential relative porphyrin enrichment in solar keratoses upon topical application of 5-aminolevulinic acid methylester. *Photochem Photobiol* 1998; 68: 218–221.
9. Sharfaei S, Juzenas P, Moan J. Weekly topical application of methyl aminolevulinate followed by light exposure delays the appearance of UV-induced skin tumours in mice. *Arch Dermatol Res* 2002; 294: 237–242.
10. Stender IM, Bech-Thomsen N, Poulsen T, Wulf HC. Photodynamic therapy with topical  $\delta$ -aminolevulinic acid delays UV photocarcinogenesis in hairless mice. *Photochem Photobiol* 1997; 66: 493–496.
11. Olsen EA, Abernethy ML, Kulp-Shorten C, Callen JP, Glazer SD, Huntley A, et al. A double-blind, vehicle-controlled study evaluating masoprocol cream in the treatment of actinic keratoses on the head and neck. *J Am Acad Dermatol* 1991; 5: 738–743.
12. National Cancer Institute Common Toxicity Criteria (version 2.0). National Cancer Institute, 30 April 1999.
13. Bavinck JN, De Boer A, Vermeer BJ, Hartevelt MM, van der Woude FJ, Claas FH, et al. Sunlight, keratotic skin lesions and skin cancer in renal transplant recipients. *Br J Dermatol* 1993; 129: 242–249.
14. Dyall-Smith D, Ross JB. Cutaneous malignancies in renal transplant recipients from Nova Scotia, Canada. *Australas J Dermatol* 1995; 36: 79–82.
15. Jensen P, Hansen S, Møller B, Leivestad T, Pfeffer P, Fauchald P, et al. Skin cancer in kidney and heart transplant recipients and different long-term immunosuppressive therapy regimens. *J Am Acad Dermatol* 1999; 40: 177–186.
16. EBPG Expert Group on Renal Transplantation. European best practice guidelines for renal transplantation. Section IV: Long-term management of the transplant recipient. IV.6 Cancer risk after renal transplantation: prevention and treatment. *Nephrol Dial Transplant* 2002; 17: 31–36.
17. DiGiovanna JJ. Retinoid chemoprevention in patients at high risk for skin cancer. *Med Pediatr Oncol* 2001; 36: 564–567.
18. Bavinck JN, Tieben LM, van der Woude FJ, Tegzess AM, Hermans J, ter Schegget J, et al. Prevention of skin cancer and reduction of keratotic skin lesions during acitretin therapy in renal transplant recipients: a double-blind, placebo-controlled study. *J Clin Oncol* 1995; 13: 1933–1938.
19. Gibson GE, O'Grady A, Kay EW, Murphy GM. Low-dose retinoid therapy for chemoprophylaxis of skin cancer in renal transplant patients. *J Eur Acad Dermatol Venereol* 1998; 10: 42–47.
20. George R, Weightman W, Russ GR, Bannister KM, Mathew TH. Acitretin for chemoprevention of non-melanoma skin cancers in renal transplant recipients. *Aust J Dermatol* 2002; 43: 269–273.
21. Szeimies RM, Karrer S, Radakovic-Fijan S, Tarew A, Calzavara-Pinton PG, Zare C, et al. Photodynamic therapy using topical methyl 5-aminolevulinate compared with cryotherapy for actinic keratosis: a prospective, randomized study. *J Am Acad Dermatol* 2002; 47: 258–262.
22. Pariser DM, Lowe NJ, Stewart DM, Jarratt MT, Lucky AW, Pariser RJ, et al. Photodynamic therapy with topical methyl aminolevulinate for actinic keratosis: results from a prospective randomized multicenter trial. *J Am Acad Dermatol* 2003; 48: 227–232.
23. Freeman M, Vinciullo C, Francis D, Spelman L, Nguyen R, Fergin P, et al. A comparison of photodynamic therapy using topical methyl aminolevulinate (Metvix) with single cycle cryotherapy in patients with actinic keratosis: a prospective, randomized study. *J Dermatol Treat* 2003; 14: 99–106.
24. Rhodes LE, de Rie M, Enström Y, Groves R, Morken T, Goulden V, et al. Photodynamic therapy using topical methyl aminolevulinate versus surgery for nodular basal cell carcinoma: results of a multicenter randomized prospective trial. *Arch Dermatol* 2004; 140: 17–23.
25. Horn M, Wolf O, Wulf HC, Warloe T, Fritsch C, Rhodes LE, et al. Topical methyl aminolevulinate photodynamic therapy in patients with basal cell carcinoma prone to complications and poor cosmetic outcome with conventional treatment. *Br J Dermatol* 2003; 149: 1242–1249.